

## UTERINE LEIOMYOMA IN A BUFFALO: A CASE REPORT

O.I. Azawi<sup>1</sup> and H.I. Al-Sadi<sup>2</sup>**ABSTRACT**

This report describes a uterine leiomyoma in a buffalo cow. This is the first description of a leiomyoma in the uterus of a buffalo cow.

**INTRODUCTION**

Leiomyomas are benign smooth muscle neoplasia (Hulland, 1990). Although, these tumors are the most common uterine neoplasia in humans (Crum, 1999) and “middle aged” or older dogs (MaClachlan and Kennedy, 2002; Sontas *et al.*, 2008), but is rare in domestic ruminants (Kennedy *et al.*, 1998; Corpa and Martinez, 2008). Little is known about the etiology and pathogenesis of leiomyoma (Sendag *et al.*, 2008). In the bitch, these tumors are often multiple neoplasms, not only in the uterus, but also in the cervix and vagina associated with ovarian follicular cysts or estrogen secreting tumors (Kennedy and Miller, 1993). The present report describes a clinical case of uterine leiomyoma in a buffalo cow.

**Case description**

A 12-year old buffalo cow, weighing 400 kg, was presented to the Department of Surgery and Theriogenology, College of Veterinary Medicine, University of Mosul, with a history of repeat breeding of more than one year and calving normally before

16 months. Her estrous cycles were irregular. Accompanying complaints were straining, decreased milk production and weight loss. This animal was a part of private buffalo dairy herd consisting of 150 buffaloes. The animals were kept outdoors near a river where they wallowed and were milked twice daily. A balanced nutritional diet including green fodder and concentrated mixture were fed to these animals.

**Clinical examination**

Physical examination of the buffalo cow revealed a normal temperature, respiration and pulse rate. The vulva was wiped clean with damp clean towels, then disinfected with iodine-povidine, and then washed again with water. A sterile vaginal speculum was lubricated with sterile Vaseline and then inserted into the vagina up to the level of the external os of the cervix. Inspection of the cervix and vagina was performed with illumination from a penlight and revealed a purulent discharge. Rectal examination of uterus revealed a very thick uterine wall and enlarged cervix and multiple follicular cysts in both left and right ovaries. Sampling for bacteriological examination was performed immediately after vaginal examination. After parting the vulval lips, an outer protective sterile plastic soft drink straw sheath was advanced into the vagina and fixed in the external opening of the cervix. A guarded inseminating pipette was advanced through the outer tube into the uterus by cervical manipulation

<sup>1</sup>Department of Surgery and Theriogenology, College of Veterinary Medicine, University of Mosul, Mosul, Iraq

<sup>2</sup>Department of Pathology, College of Veterinary Medicine, University of Mosul, Mosul, Iraq

similar to the technique for artificial insemination. The sterile swab, which was fixed on the inseminating pipette was pushed out of its protective sterile plastic drink straw sheath (to protect from contamination with cervix), and moved about slightly in the body of the uterus. After retraction into its cover, the swab was removed from the vagina, with an assistant parting the vulval lips. Swabs were transferred into sterile tubes containing thioglycolate broth as a transport media, transported to the laboratory at 4°C, and immediately processed for bacteriological examination. Biopsies were taken following the culturing procedure. Separate tissue samples were obtained from each uterine horn and the uterine body with the biopsy instrument.

## RESULTS AND DISCUSSION

Histopathological examination of the uterus of this buffalo showed a tissue of dense cellularity composed of regularly interlacing and undulating

bundles of elongate staplike smooth muscle cells and fibers (spindle cells) extensively infiltrating and expanding the uterine submucosa (Figure 1). The spindle cells had a moderate nuclear pleomorphism and were separated by collagenous matrix. The etiology of uterine leiomyoma is not known (Sendag *et al.*, 2008). Steroid hormones, especially estrogens, are thought to play a role in the pathogenesis of leiomyomas (Fiorito, 1992), as this case a multiple follicular cyst was found. Administration of exogenous hormones has been associated with the development of epithelial tumors of the endometrium in the bitch (Pena *et al.*, 2006), a true cause and effect association has not been proved. Leiomyoma in this buffalo could be due to long-term estrogen production by the multiple ovarian follicular cysts that might have played a part in the formation of the uterine leiomyoma.

Results of bacterial isolation from the uterus showed three bacterial isolates. These isolates were *Arcanobacterium pyogenes*, *Escherichia coli* and *Proteus mirabilis*. Buffalo cow bacterial

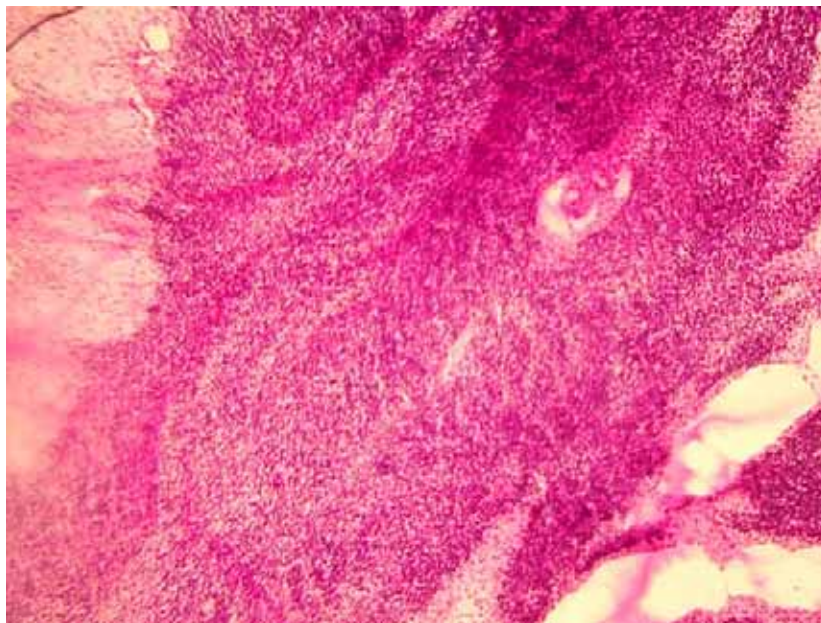


Figure 1. Leiomyoma in a buffalo cow with chronic metritis. Note that the neoplastic cells are intersecting at right angles. (H&E X 200).

contamination of the vagina and other external reproductive organs might occur during wallowing and coitus or insemination (Azawi, 2008; Azawi *et al.*, 2008). It could be suggested based on clinical outcome, bacteriological and histopathological examinations, that leiomyoma of this buffalo might predispose for bacterial infection causing metritis by lowering the uterine defense mechanism. A retrospective online search of necropsy and probably record for uterine leiomyoma in buffalo cows identified no such tumor was recorded.

## REFERENCES

- Azawi, O.I. 2008. Review: Postpartum uterine infection in cattle. *Anim. Reprod. Sci.*, **105**: 187-208.
- Azawi, O.I., S.N. Omran and J.J. Hadad. 2008. A Study of endometritis causing repeat breeding of cycling Iraqi buffalo cows. *Reprod. Domest. Anim.*, **43**: 735-743.
- Corpa, J.M. and C.M. Martinez. 2008. Uterine leiomyoma in a sheep. *Reprod. Domest. Anim.*, In press.
- Crum, P.C. 1999. The female genital tract, p. 1053-1091. In Cortan, R.S., V. Jumar, T. Collins (eds.) *Pathologic Basis of Disease*. WB Saunders, Philadelphia.
- Fiorito, D.A. 1992. Hyperestrogenism in bitches. *Compend. Cont. Educ. Pract. Vet.*, **14**: 727-729.
- Hulland, T.J. 1990. Tumors of the muscle, p. 88-101. In Moulton, J.E. (ed.) *Tumors of Domestic Animals*. Los Angeles University, California Press.
- Kennedy P.C. and R.B. Miller. 1993. The female genital system, p. 349-470. In Jubb, K.F.V., P.C. Kennedy and N. Palmer (eds.) *Pathology of Domestic Animals*, 4<sup>th</sup> ed., Vol. 3. Academic Press, San Diego, CA.
- Kennedy, P.C., J.M. Cullen, J.F. Edwards, M.H. Goldschmidt, S. Larsen and S. Nielsen. 1998. Tumors of the uterus, p. 32-33. In Schulman, F.Y. (ed.) *Histological Classification of Tumors of the Genital System of Domestic Animals*. Armed Forces Institute of Pathology, Washington, DC.
- MaClachlan, N.J. and P.C. Kennedy. 2002. Tumors of the genital system, p. 547-573. In Meuten, D.J. (ed.) *Tumors in Domestic Animals*, 4<sup>th</sup> ed. Iowa State Press, Iowa.
- Pena, F.J., J.A. Gines, J. Duque, V. Vieitez, R. Martinez-Perez, L. Madejon, I. Nunez Martinez, J.M. Moran and S. Fernandez-Garcia. 2006. Endometrial adenocarcinoma and mucometra in a 6-year-old Alaska Malamute Dog. *Reprod. Domest. Anim.*, **41**: 189-190.
- Sendag, S., Y. Cetina, M. Alana, F. Ilhana, F. Eskia and A. Wehrendb. 2008. Cervical leiomyoma in a dairy cattle. *Anim. Reprod. Sci.*, **103**: 355-350.
- Sontas, B.H., H. Ozyogurtcu, O. Turna, S. Arun and H. Ekici. 2008. Uterine leiomyoma in a spayed poodle bitch: A case report. *Reprod. Domest. Anim.*, In press.